

Foramen of Winslow hernia requiring right hemicolectomy

A 73-year-old female presented acutely with a 12-h history of cramping intermittent, generalized abdominal pain with recurrent vomiting. This is in the background of known gallstones and no previous surgical history. Vital signs were within normal ranges and the patient was mildly tender in the epigastrium with no palpable mass or peritonism. Bloods showed mixed deranged liver function tests, other blood results were within normal limits. Computed tomography scan of the abdomen and pelvis showed distal small bowel and right colon herniating through the foramen of Winslow into the lesser sac (Fig. 1). There was evidence of early vascular compromise with submucosal oedema and mesenteric hyperaemia of the small bowel within the lesser sac. CT also demonstrated compression of the hepatoduodenal ligament and subsequent displacement and narrowing of the superior mesenteric and portal vein confluence, explaining the deranged LFTs.

An emergent laparotomy was performed that same day which showed terminal ileum, caecum and ascending colon herniating through the foramen of Winslow (Figs 2 and 3). The herniated bowel was unable to be reduced through the foramen of Winslow; thus, the lesser sac was entered through the gastrocolic omentum

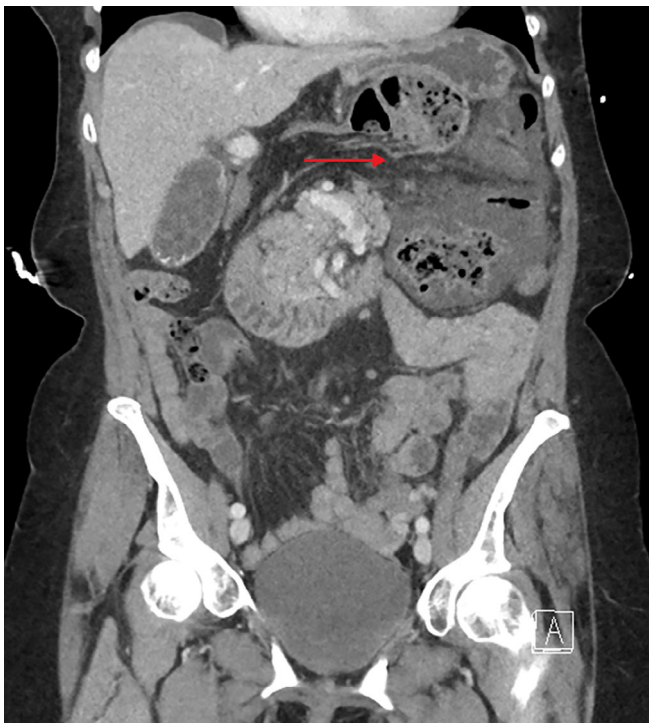

Fig. 1. Bowel passing through the foramen of Winslow on coronal slices on CT (arrow).

revealing patching necrosis of the right colon. A right hemicolectomy was performed with terminal ileum and mid-transverse colon transected with GIA 80 stapler to the right of the porta hepatis, and the mesentery divided from the lesser sac side. A stapled side-to-side anastomosis was performed, the mesenteric defect closed and the Foramen of Winslow left open. The post-operative course was uneventful.

Foramen of Winslow hernias are extremely rare and account for only 0.08% of all hernias.¹ The proposed mechanism of this hernia involves excessive viscera mobility, abnormal enlargement of the foramen of Winslow and changes in intra-abdominal pressure.^{2,3} A foramen of 3 cm is considered wide enough to allow viscera to herniate through.² Most presentations of Foramen of Winslow hernias are usually non-specific other than acute upper abdominal pain and symptoms related to bowel obstruction. Occasionally, there is a

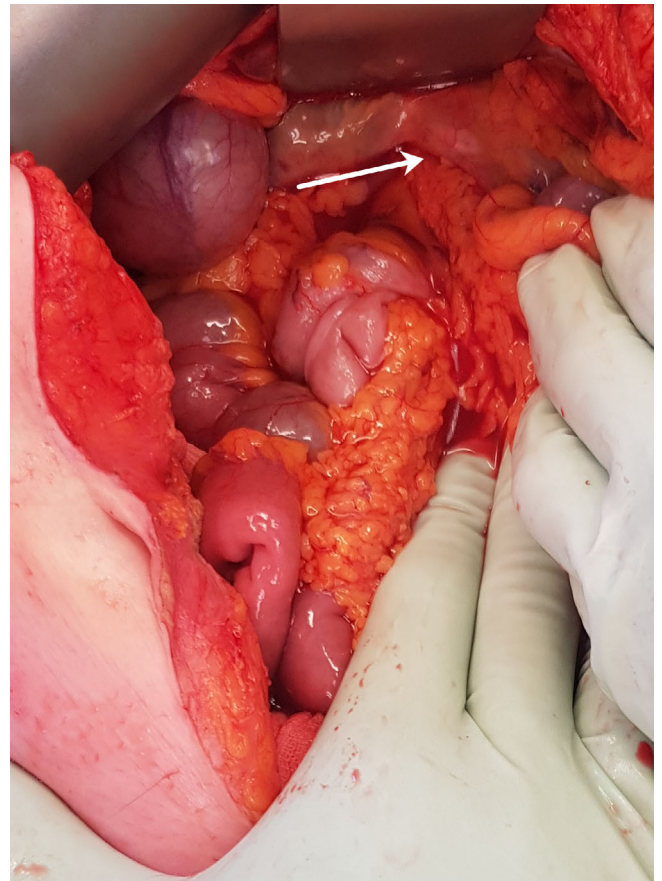


Fig. 2. Ascending colon traversing the foramen of Winslow (arrow hepatoduodenal ligament).

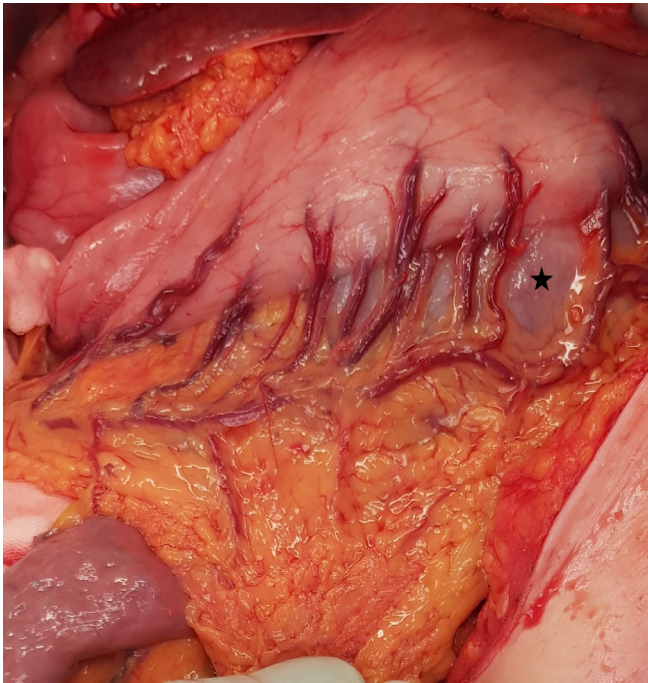


Fig. 3. Caecum visible in the lesser sac behind the stomach (star).

history of chronic or recurring abdominal pain prior to the acute presentation that is presumably from a self-reducing hernia. Cross-sectional imaging is the main diagnostic tool, with the presence of bowel loops in the lesser sac in between the stomach anteriorly and pancreas posteriorly, diagnostic of this condition.³

Other imaging signs include narrowing of the portal vein and extrahepatic biliary system, which can manifest as ischaemic hepatitis and jaundice, respectively.^{4,5} Surgical intervention is the mainstay treatment, with laparotomy being the approach of choice.² However, there are case reports of successful laparoscopic approaches and techniques to prevent recurrence. These techniques can include closure of the foramen, caecopexy or right colonic fixation.² However, there are no documented case reports of Foramen of Winslow hernia recurrence in the literature. Clinicians need to consider internal hernias in their differential diagnosis of an acute

abdomen with early cross-sectional imaging and surgical intervention. Clinical examination and investigations may be misleading and high index of suspicion is necessary to diagnose these rare entities.

Author contributions


Alain Nguyen: Conceptualization; data curation; formal analysis; writing – original draft; writing – review and editing. **Adam Schofield:** Conceptualization; supervision; writing – review and editing. **Conrad Viktor Stranz:** Supervision; writing – review and editing. **Mathew Ollapallil Jacob:** Writing – review and editing.


References

1. Osvaldt A, Mossmann D, Bersch V, Rohde L. Intestinal obstruction caused by a foramen of Winslow hernia. *Am. J. Surg.* 2008; **196**: 242–4.
2. Moris D, Tsilimigras D, Yerokun B *et al.* Foramen of Winslow hernia: a review of the literature highlighting the role of laparoscopy. *J. Gastrointest. Surg.* 2019; **23**: 2093–9.
3. Martin L, Merkle E, Thompson W. Review of internal hernias: radiographic and clinical findings. *AJR Am. J. Roentgenol.* 2006; **186**: 703–17.
4. Yamashiro T, Ikeda H, Fujikawa A *et al.* Internal hernia through the foramen of Winslow: the “narrowed portal vein” sign on abdominal CT. *Emerg. Radiol.* 2012; **20**: 247–50.
5. Koh C, Woods S, Usatoff V. Foramen of Winslow hernia. *Surg. Pract.* 2007; **11**: 81–3.

Alain Nguyen,* MD 

Adam Schofield,† MD, FRCS

Conrad Viktor Stranz,‡ MBBS, FRACS 

Mathew Ollapallil Jacob,‡ MBBS, FRACS 

*Upper Gastrointestinal Unit, Lyell McEwin Hospital, Elizabeth Vale, South Australia, Australia, †Upper Gastrointestinal Unit, Royal Adelaide Hospital, Adelaide, South Australia, Australia and ‡Colorectal Unit, Lyell McEwin Hospital, Elizabeth Vale, South Australia, Australia

doi: 10.1111/ans.18086